

<https://doi.org/10.15407/exp-oncology.2025.03.369>

A. Moiseienko *, V. Dibrova, O. Melnyk

O.O. Bogomolets National Medical University, Kyiv, Ukraine

* Correspondence: Email: a.moysenko1977@gmail.com

DIAGNOSIS AND SURGICAL TREATMENT OF GASTROINTESTINAL STROMAL TUMORS OF THE STOMACH USING MINIMALLY INVASIVE TECHNOLOGIES

Background. Gastrointestinal stromal tumors of the stomach (GIST) are relatively rare, and in 65% of cases, their primary localization is the stomach wall. Considering that the incidence of GIST is 1.2 cases per 10^5 people per year, not all aspects of the treatment and diagnostic tactics are sufficiently studied. **The aim** of the study was to examine the possibilities of modern methods of preoperative verification of GIST of the stomach and the effectiveness of their surgical treatment using minimally invasive technologies. **Materials and Methods.** We analyzed the results of surgical treatment using minimally invasive technologies for 24 GIST patients with tumor localization in the stomach wall treated in the clinic of the Bogomolets National Medical University in 2017—2025. Histological and immunohistochemical analyses of the biopsy and surgical materials were performed. **Results.** The choice of a method for performing gastric resection depended on the localization and size of the tumor, and the type of its growth. Of 17 (70.8%) patients with the exophytic type of GIST growth, 13 (54.2%) patients had significant difficulties with verification of the tumor in the gastric wall during laparoscopic revision. **Conclusion.** The results of the study are consistent with international data and emphasize the need for morphological typing and the use of immunohistochemical markers for accurate diagnosis, risk stratification, and selection of further treatment tactics for patients with GIST of the stomach.

Keywords: GIST of the stomach, biopsy, laparoscopic gastric resection, intraoperative fibrogastroduodenoscopy, immunohistochemistry.

According to current statistics, gastrointestinal stromal tumors (GIST) occur at a frequency of 1.2 cases per 10^5 people per year, which is 0.1% of the total number of all tumors of the digestive tract [1, 2]. Scientific data on the origin of GIST still remain controversial. In particular, there are no studies that convincingly prove the presence of a genetic predisposition to this disease and the possibility of its inheritance in generations [1, 2]. GISTs develop from

interstitial cells of Cajal or their precursors as a result of the occurrence of spontaneous mutations in proto-oncogene coding for tyrosine kinase receptor c-KIT (CD 117) [3]. It is the activity of c-KIT receptors that determines the direction of differentiation of mesenchymal precursor cells into Cajal cells, and in the absence of these receptors, into smooth muscle cells [4]. GISTs are malignant neoplasms of the digestive tract of mesenchymal origin, which in 65%

Citation: Moiseienko A, Dibrova V, Melnyk O. Diagnosis and surgical treatment of gastrointestinal stromal tumors of the stomach using minimally invasive technologies. *Exp Oncol.* 2025; 47(3): 369-376. <https://doi.org/10.15407/exp-oncology.2025.03.369>

© PH «Akademperiodyka» of the NAS of Ukraine, 2025. This is an open access article under the CC BY-NC-ND license (<https://creativecommons.org/licenses/by-nc-nd/4.0/>)

of cases have a primary localization in the stomach wall [5]. These tumors do not have specific clinical manifestations and are detected more often by chance, during a preventive examination with fibrogastroduodenoscopy (FGDS) or against the background of gastrointestinal bleeding, which is their most frequent complication [4–6]. GIST, although it is the most common tumor of the digestive tract of mesenchymal origin, is relatively rare [7]. There is a fairly large number of publications devoted to this topic, but they are based on a small number of observations, which probably explains the existence of many aspects of the diagnosis and treatment of GIST, which require further study [8]. In particular, given the intramural localization of GIST in the gastric wall, some authors point to significant difficulties in obtaining biopsy material for the preoperative verification of this disease with a high frequency of false-negative results [9]. The question of choosing the tactics of surgical treatment of GIST, in particular, the possibility of performing surgery and the volume of minimally invasive methods of

surgical interventions in this pathology, also requires further study [10, 11].

The aim of the study was to examine the possibilities of current methods of the preoperative verification of gastric GIST and to analyze the effectiveness of their surgical treatment using minimally invasive technologies.

Materials and Methods

Over 2017–2025, 24 patients, 9 men and 15 women, who were diagnosed with GIST with tumor localization in the stomach wall, were treated in the clinic of the Department of Surgery No. 2 of the Bogomolets National Medical University. The age of the patients ranged from 41 to 78 years; the average age was 57.1 ± 8.65 years. The standard scope of instrumental examinations in all patients included fluoroscopy and computed or magnetic resonance imaging with intravenous contrast. Based on the analysis of the results of additional research methods, the criteria for the possibility of surgical treatment of gastric GIST using minimally invasive technologies were determined. The study did not include patients with verified gastric GIST with distant metastases, dissemination throughout the peritoneum, tumor spread to neighboring organs, or combination with tumors of other localization, in particular, in the presence of gastric GIST and colon cancer. Histological and immunohistochemical examination of the obtained biopsy and surgical materials was performed. A risk of recurrence and progression of the disease was determined based on the recommendations of the National Institute of Pathology of the US Armed Forces (United States Armed

Table 1. Morphological criteria for the risk of recurrence and prolongation of GIST

Risk category	Number of mitoses/5 mm ²	Tumor size (cm)
1	≤ 5	≤ 2
2		>2 to ≤ 5
3a		>5 to ≤ 10
3b		>10
4	>5	≤ 2
5		>2 to ≤ 5
6a		>5 to ≤ 10
6b		>10

Table 2. Distribution of patients with GIST by tumor location in the stomach

Localization of GIST	Anterior wall	Posterior wall	Total (%)
Cardiac part	1	1	2 (8.33%)
Fundus of the stomach	1	—	1 (4.18%)
Body of the stomach:			5 (20.83%)
Closer to the lesser curvature	2	3	8 (33.33%)
Closer to the greater curvature	1	7	
Prepyloric part:			2 (8.33%)
Closer to the lesser curvature	1	1	6 (25%)
Closer to the greater curvature	3	3	
Total, %	9 (37.5%)	15 (62.5%)	24 (100%)

Forces Institute of Pathology—AFIP), which is given in Table 1 [10].

Results

We studied and analyzed the results of surgical treatment of 24 patients with gastric GIST who were treated in the clinic using minimally invasive technologies. Of these, 22 (91.7%) patients had gastric GIST diagnosed during fluoroscopy, and the other 2 (8.3%) patients were diagnosed accidentally during an abdominal CT scan, with subsequent endoscopic confirmation. The distribution of patients with gastric GIST depending on its localization is presented in Table 2.

The localization of the tumor and the type of its growth are factors that largely determine the choice of the tactics and volume of the surgical intervention, which are of exceptional importance in laparoscopic surgery. In the studied group, patients with GIST localization on the posterior wall of the stomach prevailed (Table 2). In the process of FGDS, exophytic tumor growth was detected in the vast majority — 17 (70.8%) patients, with 5 of them showing signs of ulceration of the gastric mucosa on its surface and 7 (29.2%) patients showing endophytic growth of the neoplasm.

It should be noted that in 10 (41.7%) patients, GIST at the time of diagnosis verification did not have any specific clinical manifestations, and there were incidental findings during prophylactic FGDS (8 patients) and during CT of the abdominal cavity (2 patients). The other 7 (29.2%) patients were hospitalized urgently with the signs of gastrointestinal bleeding (GIB). At the same time, the presence of ulceration of the tumor surface was not a mandatory attribute for the occurrence of GIB. Of the 5 patients with ulceration of the gastric mucosa on the tumor surface, the signs of GIB occurred in 3 cases. In the remaining cases, despite the presence of ulcers on the tumor surface, no clinical or laboratory signs of GIB were detected. Pain in the epigastric region was observed on the background of GIST in 5 (20.8%) patients. 1 patient with tumor localization in the subcardiac part of the stomach had dysphagia, heartburn, and periodic vomiting of food. In the other 2 patients, GIST in the prepyloric part of the stomach was manifested by symptoms of partial violation of evacuation from the stomach — a feeling of heaviness in the epigastrium after eating, belching with

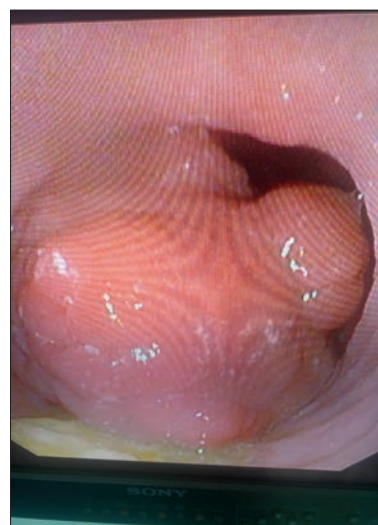

Fig. 1. Endoscopic picture of the prepyloric part of the stomach. On the posterior wall closer to the greater curvature, a GIST of 82 × 68 mm was determined, which was accompanied by clinical manifestations of impaired evacuation function of the stomach

air, nausea, and vomiting (Fig. 1). To verify the diagnosis at the prehospital stage, preoperative tumor biopsy was performed in 14 (58.3%) patients. Of these, fine-needle biopsy under endosonographic control was performed in 3 patients, and in 5 patients with signs of ulceration of the tumor surface detected during EGD (Fig. 2), traditional endoscopic biopsy using forceps was performed. In the obtained biopsy material in all these patients, GIST cells were verified during histological and immunohistochemical studies. In 6 more patients with signs of exophytic growth of the neoplasm, an incisional endoscopic biopsy was performed. The signs of tumor growth in the material obtained in this way were detected only in 1 patient; the other 5 samples were pseudonegative (Fig. 3), while in the study of the surgical material, in all cases, the tumors were verified as GIST.

In the process of surgical treatment of all patients with gastric GIST, the organ-preserving laparoscopic interventions were performed. In all cases, surgical interventions were performed using 4 ports: a 10 mm video port located infraumbilically, a universal port 5—15 mm in the left subcostal region, and two ports with a diameter of 5 mm in the epigastric and right subcostal regions. In the case of localization of the tumor on the posterior wall of the stomach, a partial dissection of the gastrocolic ligament was performed to provide access to the tumor through the omental bag. In all cases, to provide access to the omental

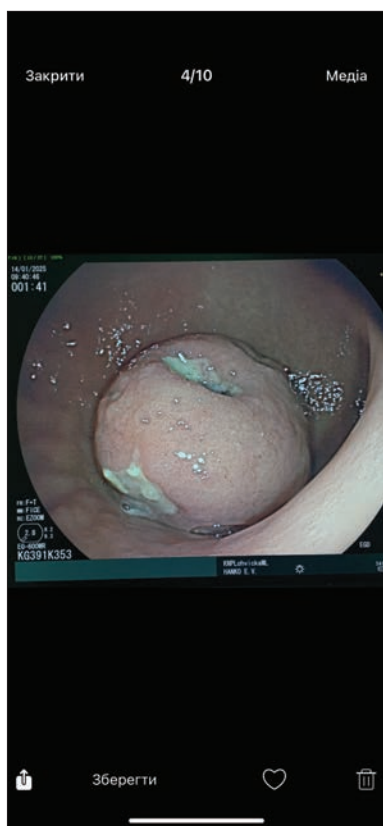


Fig. 2. Endoscopic picture of the stomach. On the posterior wall closer to the lesser curvature, a GIST of 34 × 32 mm was detected with signs of surface ulceration and no signs of bleeding

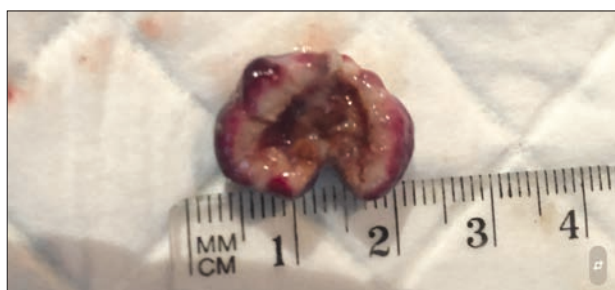

Fig. 3. Incisional endoscopic biopsy of the stomach wall in the projection of the neoplasm. A fragment of the stomach wall of 19 × 11 mm was obtained. No sign of tumor growth was detected in the studied preparation

bursa, if necessary, to perform lymphodissection and, in some cases, to perform the mobilization stage of the macropreparation, the Ligasure electroligating generator was used with the use of a laparoscopic Maryland dissector with a diameter of 5 mm. The choice of the method of performing gastric resection depended on the localization of the tumor, its size and type of growth. In the case of exophytic type of tumor growth, especially when localized on the anterior wall of the stomach. The tumor is easily

identified during laparoscopic revision of the abdominal organs. This type of tumor growth occurred in 7 (29.2%) patients. In 5 of them, GIST on the pedicle was detected; in these patients, we performed laparoscopic sectoral or segmental gastric resections using a linear 3-row endostapler. In most cases, 2 stapler cassettes of 60 and 45 mm were used sequentially. In the other 2 patients with tumor localization near the lesser curvature of the stomach, their removal was performed using an ultrasonic dissector with subsequent suturing of the stomach with an intracorporeal suture. Of the 17 (70.8%) patients with the exophytic type of GIST growth, 13 (54.2%) patients had significant difficulties with verification of the tumor in the stomach wall during laparoscopic revision. Tumors up to 20 mm in size were especially difficult to identify. In all cases, to establish the topography of GIST and determine the volume of laparoscopic gastric resection, we used intraoperative FGDS. In 15 patients, we performed laparoscopic sectoral or segmental gastric resections. In 2 (8.33%) patients with large tumors of the prepyloric part of the stomach (Fig. 1), we performed laparoscopically assisted gastric resections. For this, a microlaparotomy was performed along the midline at the level of the pyloric part of the stomach, with subsequent installation of a hand port. After completing the mobilization stage of the operation, the macropreparation was placed in a container before removing it from the abdominal cavity in order to comply with the principles of ablatics. There were no cases of intraoperative tumor damage at the stage of mobilization or removal from the abdominal cavity. The status of the resection margins in all cases was histologically determined as R0.

The final clinical diagnosis of GIST in all patients was confirmed on the basis of histological and immunohistochemical examination of macropreparations. At the light-optical level, it was established that in most cases (16 patients; 66.7%), GIST had a spindle cell morphological structure (Fig. 4). A mixed cell type was detected in 5 cases (20.8%), while the epithelioid variant was observed in 3 patients (12.5%). The immunohistochemical examination showed the presence of strong positive expression of CD117 (c-KIT) receptors in all analyzed samples (100%) (Fig. 5). The proliferative activity index by the Ki-67 marker varied from 10% to 15% (Fig. 6), which indicated moderate proliferative activity of tumor cells. The distribution of patients who under-

went laparoscopic surgery for gastric GIST according to morphological categories of risk of recurrence and disease prolongation, is presented in Table 3.

Discussion

The recommendations of the European Society of Gastrointestinal Endoscopy provide for routine endoscopic diagnostics with biopsy under endosonographic control in cases of gastric GIST with dimensions greater than 20 mm; as for tumors within 10–20 mm, their endoscopic submucosal dissection is allowed [12]. However, the recommendations note that this tactic does not have a sufficient evidence base. The removal of gastric GIST less than 20 mm by endoscopic means is called an acceptable alternative to other surgical methods of treatment. At the same time, it is recognized that the choice of a method of surgical treatment of GIST depends on the size of the tumor, its localization, and the experience of the performers. Currently, there is no unified tactic for the use of puncture biopsy at the stage of preoperative examination of patients with gastric GIST. Some authors recommend refraining from performing it at the preoperative stage, motivating this by the increased risk of implantation of tumor cells through the puncture channel [3, 5]. However, Jacob et al. [13], citing a number of meta-analyses, indicate the absence of a significant increase in the incidence of GIST recurrence in patients after preoperative biopsy. We drew attention to the high informativeness of traditional endoscopic biopsy in the examination of patients with gastric GIST who had signs of ulceration of the tumor surface. In all 5 patients, in the biopsy material taken with forceps from the ulcer bottom on the GIST surface, cellular atypia was histologically confirmed. At the same time, incisional endoscopic biopsy, even with wide tissue capture in the projection of the tumor node with its exophytic growth (Fig. 3), turned out to be low informative. The results obtained confirm the high diagnostic value of a comprehensive morphological approach using light microscopy and immunohistochemical methods in the verification of gastric GIST. The predominance of the spindle cell morphological variant (66.7%) is consistent with the literature, where this type is considered the most common among gastric GISTs. Epithelioid and mixed types are much less common, which is also confirmed in our study (12.5% and 20.8%, respectively).

High expression of CD117 (c-KIT) in 100% of samples indicates stable expression of this receptor in most GISTs, which is consistent with current understanding of the pathogenesis of these tumors, in particular, the role of mutations in the *KIT* gene [3]. This marker remains one of the key ones for immunohistochemical diagnosis of GIST. In operated patients, we established a proliferation index for Ki-67 of 10%–15%, which allows us to classify most tumors as having moderate proliferative activity. Although this indicator is not the only criterion for malignant potential, its increase may be associated with more aggressive tumor behavior and a higher risk of recurrence. Thus, the determination of Ki-67 is appropriate as an additional prognostic marker. The results of the study are consistent with international data and emphasize the need for morphological typing and the use of immunohistochemical markers for accurate diagnosis, risk stratification, and selection of further treatment tactics for patients with gastric GIST [10].

Recently, the number of supporters of surgical treatment of gastric GIST using laparoscopic surgery has been increasing, but still, certain limitations in their use remain [14–17]. In particular, some authors point to a higher risk of possible disruption of the tumor integrity with laparoscopic instruments during its mobilization compared to open surgery [3]. Intraoperative damage to GIST is a factor that, with a high degree of evidence, contributes to the occurrence of disease recurrence [10]. To reduce the likelihood of this complication, it is recommended not to operate laparoscopically on patients with gastric GIST in whom the tumor size exceeds 50 mm

Table 3. Assessment of the risk of recurrence and prolongation of GIST in patients after laparoscopic gastric resection

Risk category	Number of patients	Number of relapses
1	4	—
2	7	—
3a	3	—
3b	1	—
4	2	—
5	6	1
6a	1	1
6b	—	—
Total, %	24 (100%)	2 (8.33%)

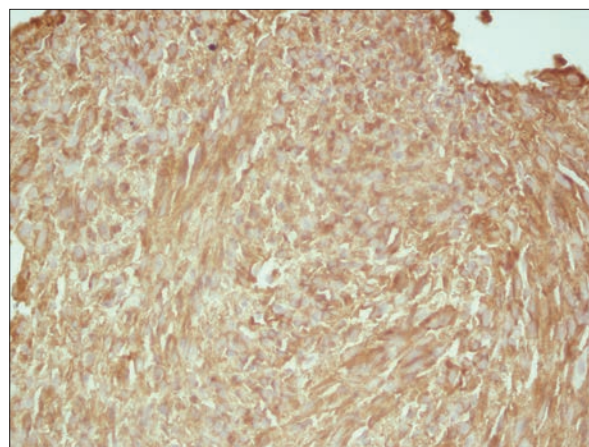
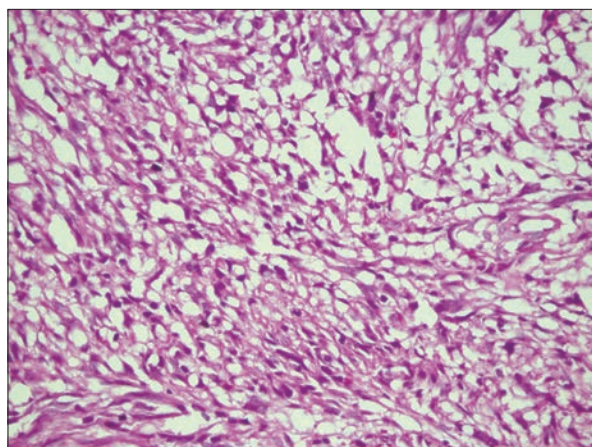


Fig. 4. Pathohistological picture of a GIST of the stomach; spindle cell type. Hematoxylin-eosin stain. $\times 100$. In the histological material, tumor tissue of a lobular structure is represented by strands of spindle-shaped cells with pale eosinophilic cytoplasm and round or elongated hyperchromic nuclei. Degenerative changes of cells are observed, manifested by the formation of multiple perinuclear vacuoles. There are areas of hyalinosis and sclerosis of the stroma and diffuse lymphoid infiltration. The number of mitoses is >5 per 5 mm^2 in 50 fields of view with a magnification of $\times 100$

Fig. 5. Cytoplasmic expression of CD117 by tumor cells. IHC with CD117. $\times 100$

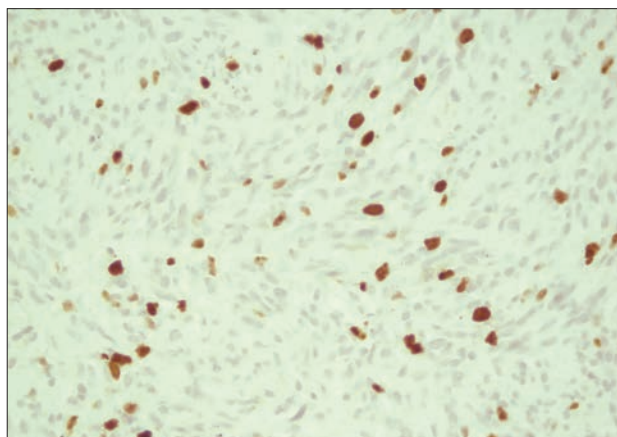


Fig. 6. Nuclear expression of Ki-67 by tumor cells. IHC with Ki-67. $\times 100$

[18]. Potentially difficult for laparoscopic treatment are also GISTs localized on the posterior wall of the stomach near the cardia. Laparoscopic operations in such cases result in a significantly higher frequency of complications, such as failure of the gastric suture and impaired motor function with the development of dysphagia [14]. A number of authors note the high effectiveness of surgical treatment of gastric GIST using laparoscopic technologies at the initial stages of the disease, when the tumor size is within 20–30 mm [13, 17]. However, when performing laparoscopic operations for gastric GIST with exophytic tumor growth and its size up to 20 mm, we encountered significant difficulties in identifying it in the gastric wall and determining the boundaries of resection. This problem was especially relevant

when the tumor was localized on the posterior wall of the stomach [19]. In our opinion, the real incidence rate of gastric GIST is much higher than official statistics suggest, since these tumors are difficult to identify even endoscopically at the early stages of the disease [20, 21]. Laparoscopic gastric resection in the mode of dual tumor visualization using intraoperative FGDS in 13 (54.2%) patients allowed us to identify the tumor in the gastric wall and perform radical resection. At the same time, endoscopic transillumination from the side of the gastric lumen allows us to visualize the tumor against the background of the architectonics of the large vessels of its wall, which improves the quality of intraoperative hemostasis.

To sum up, the determining factor influencing the results of laparoscopic gastric resection for GIST is the assessment of its resectability based on CT of the abdominal organs and EGD. The criteria for the possibility of performing GIST by laparoscopic surgery are the assessment of the size and location of the tumor and the absence of extra-organ germination and distant metastases. The most effective methods for obtaining biopsy material at the stage of preoperative examination are performing fine-needle biopsy of GIST under endosonographic control and, in cases of ulceration of its surface, taking material directly from the ulcer bottom. In the absence of technical capabilities for their implementation in conditions of resectable GIST, it is advisable to refrain from performing preoperative biopsy by

another method. Performing laparoscopic gastric resection in the dual visualization mode in combination with intraoperative FGDS allows for the increased radicality of surgical intervention due to the rapid visualization of the tumor, determination of

safe resection margins, and avoidance of its damage at the beginning of the mobilization stage. The impact of the method of performing preoperative gastric GIST biopsy on the risk of tumor recurrence requires further study.

REFERENCES

1. Blay JY, Kang YK, Nishida T, von Mehren M. Gastrointestinal stromal tumours. *Nat Rev Dis Primers*. 2021;7(1):22. <https://doi.org/10.1038/s41572-021-00254-5>
2. Alvarez CS, Piazuolo MB, Fleitas-Kanonnikoff T, et al. Incidence and survival outcomes of gastrointestinal stromal tumors. *JAMA Netw Open*. 2024;7(8):e2428828. <https://doi.org/10.1001/jamanetworkopen.2024.28828>
3. Moga D, Popentiu A, Popa D. Laparoscopic wedge resection for gastric mesenchymal tumor—small case series. *Rom J Mil Med*. 2023;126:239-244. <https://doi.org/10.55453/rjmm.2023.126.3.1>
4. Doru-Florian-Cornel M, Gabriela V, Anca-Maria F, et al. Understanding gastric GIST: from pathophysiology to personalized treatment. *J Clin Med*. 2024;13(14):3997. <https://doi.org/10.3390/jcm13143997>
5. Kelly CM, Gutierrez Sainz L, Chi P. The management of metastatic GIST: current standard and investigational therapeutics. *J Hematol Oncol*. 2021;14(1):2. <https://doi.org/10.1186/s13045-020-01026-6>
6. Zahidin MSI, Singh J, Azmi SM, et al. Gastrointestinal stromal tumor (GIST) in upper gastrointestinal masquerade anaemia. *Cureus*. 2024;16(6):e62409. <https://doi.org/10.7759/cureus.62409>
7. Shanker DA, Kumar S, Al-Mukhtar A, et al. A Case of gastrointestinal stromal tumour (GIST) in the duodenum in a young adult. *Cureus*. 2024;16(1):e53331. <https://doi.org/10.7759/cureus.53331>
8. Abdalla TSA, Pieper L, Kist M, et al. Gastrointestinal stromal tumors of the upper GI tract: population-based analysis of epidemiology, treatment and outcome based on data from the German Clinical Cancer Registry Group. *J Cancer Res Clin Oncol*. 2023;149(10):7461-7469. <https://doi.org/10.1007/s00432-023-04690-6>
9. Gheorghe G, Bacalbasa N, Ceobanu G, et al. Gastrointestinal stromal tumors — a mini review. *J Pers Med*. 2021;11(8):694. <https://doi.org/10.3390/jpm11080694>
10. Serrano C, Martín-Broto J, Asencio-Pascual JM, et al. 2023 GEIS Guidelines for gastrointestinal stromal tumors. *Ther Adv Med Oncol*. 2023;15:17588359231192388. <https://doi.org/10.1177/17588359231192388>
11. Zalberg JR. Ripretinib for the treatment of advanced gastrointestinal stromal tumor. *Therap Adv Gastroenterol*. 2021;14:17562848211008177. <https://doi.org/10.1177/17562848211008177>
12. Deprez PH, Moons LMG, O'Toole D, et al. Endoscopic management of subepithelial lesions including neuroendocrine neoplasms: European Society of Gastrointestinal Endoscopy (ESGE) Guideline. *Endoscopy*. 2022;54(4):412-429. <https://doi.org/10.1055/a-1751-5742>
13. Jakob J, Salameh R, Wichmann D, et al. Needle tract seeding and abdominal recurrence following pre-treatment biopsy of gastrointestinal stromal tumors (GIST): results of a systematic review. *BMC Surg*. 2022;22(1):202. <https://doi.org/10.1186/s12893-022-01648-2>
14. Capuano M, Palomba G, Sorrentino G, et al. Laparoscopic atypical resection of subcardial gastric GIST guided by intraoperative endoscopy. A single-center study and a review of the literature. *Ann Ital Chir*. 2022;11:S2239253X22038750
15. Ortenzi M, Ghiselli R, Cardinali L, Guerrieri M. Surgical treatment of gastric stromal tumors: laparoscopic versus open approach. *Ann Ital Chir*. 2017;88:S0003469X17026112. PMID: 28604382
16. Morales-Conde S, Socas M, Alarcón I, et al. Classification of GIST and other benign gastric tumors based on minimally invasive surgical strategy. *Langenbecks Arch Surg*. 2023;409(1):3. <https://doi.org/10.1007/s00423-023-03203-w>
17. Yabe N, Takenoya T, Oto I, et al. A case of recurrent gastric GIST who survived for long after laparoscopic resection and imatinib therapy. *Cancer Chemother*. 2023;50(13):1718-1720. PMID: 38303184
18. Wu X, Sun LD, Wang M, et al. Efficacy comparison between laparoscopy and open surgery in the treatment of gastric gastrointestinal stromal tumors larger than 2 cm using multicenter propensity score matching method. *Chin J Gastrointest Surg*. 2020;23(9):888-895. <https://doi.org/10.3760/cma.j.cn.441530-20200616-00366>
19. Teng TZJ, Ishraq F, Chay AFT, Tay KV. Lap-Endo cooperative surgery (LECS) in gastric GIST: updates and future advances. *Surg Endosc*. 2023;37(3):1672-1682. <https://doi.org/10.1007/s00464-022-09691-z>
20. Kolosovych IV. Helicobacter pylori and its role in the pathogenesis of diseases of the digestive system. *Fiziol Zh*. 2024;70(5):108-120. <https://doi.org/10.15407/fz70.05.108>
21. Hallak YO, Karajeh O, Rivas H, Helling K. Incidental gastrointestinal stromal tumors (GIST) during laparoscopic sleeve gastrectomy procedures: a retrospective study. *Obes Surg*. 2022;32(1):3-7. <https://doi.org/10.1007/s11695-021-05770-7>

Submitted: April 23, 2025

А. Мойсеєнко, В. Діброва, О. Мельник
Національний медичний університет
ім. О.О. Богомольця, Київ, Україна

ДІАГНОСТИКА І ХІРУРГІЧНЕ ЛІКУВАННЯ
ГАСТРОІНТЕСТИНАЛЬНИХ СТРОМАЛЬНИХ
ПУХЛИН ШЛУНКУ ІЗ ЗАСТОСУВАННЯМ
МІНІІНВАЗИВНИХ ТЕХНОЛОГІЙ

Стан питання. Гастроінтестинальні стромальні пухлини шлунку (ГІСП) є представниками злоякісних новоутворень травного тракту, які зустрічаються порівняно рідко, і в 65% випадків їх первинною локалізацією є стінка шлунку. Враховуючи, що захворюваність на ГІСП складає 1,2 випадків на 10^5 осіб на рік, не всі аспекти лікувально-діагностичної тактики є достатньо вивченими. **Мета роботи.** Вивчити можливості сучасних методів доопераційної верифікації ГІСП шлунка та ефективність їх хірургічного лікування із застосуванням мініінвазивних технологій. **Матеріали і методи.** Впродовж 2017—2025 років в клініці кафедри хірургії №2 Національного медичного університету імені О.О. Богомольця було проліковано 24 хворих, 9 чоловіків та 15 жінок, у яких були діагностовані ГІСП з локалізацією пухлини в стінці шлунка. Усім хворим виконано гістологічне та імуногістохімічне дослідження отриманого біопсійного та операційного матеріалу. **Результати.** Вивчено та проаналізовано результати хірургічного лікування 24 хворих на ГІСП шлунка, що були прооперовані в клініці із застосуванням мініінвазивних технологій. Вибір способу виконання резекції шлунка залежав від локалізації пухлини, її розмірів та типу росту. З 17 (70,8%) хворих з екзофітним типом росту ГІСП, у 13 (54,2%) пацієнтів були суттєві труднощі з верифікацією пухлини в стінці шлунка під час лапароскопічної ревізії. **Висновок.** У процесі хірургічного лікування всіх хворих з ГІСП шлунка були виконані органозберігаючі лапароскопічні втручання. Результати дослідження узгоджуються зі світовими даними та підкреслюють необхідність морфологічного типування і застосування імуногістохімічних маркерів для точної діагностики, стратифікації ризиків та вибору подальшої тактики лікування хворих на ГІСП шлунку.

Ключові слова: ГІСП шлунку, біопсія, лапароскопічна резекція шлунка, інтраопераційна фіброгастроуденоскопія, імуногістохімія.