

<https://doi.org/10.15407/exp-oncology.2024.01.073>

**V. CHESHUK<sup>1,\*</sup>, M. ANIKUSKO<sup>2</sup>, V. KOZINA<sup>2</sup>, V. ULISHCHENKO<sup>1</sup>, M. MALEC<sup>2</sup>**

<sup>1</sup> Bogomolets National Medical University, Kyiv, Ukraine

<sup>2</sup> Kyiv City Clinical Oncology Center, Kyiv, Ukraine

\* Correspondence: Email: [v.cheshuk@gmail.com](mailto:v.cheshuk@gmail.com)

## **VIRGINAL RECURRENT GIGANTOMASTIA (BREAST HYPERTROPHY). A CASE REPORT**

Virginal gigantomastia (VGM) is a benign disease of the breasts without a clearly established etiology. The treatment of VGM remains a problem. The conservative treatment is not effective while surgery is too traumatic. Most specialists recommend subcutaneous mastectomy with immediate implant reconstruction or reduction mammoplasty. The reduction mammoplasty with adjuvant hormone therapy is a variant of treatment of young patients with a risk of recurrence. We present a case of a patient with VGM who was operated in 2014. Reduction mammoplasty was performed. After 9 years, the patient had a relapse and second surgery, resection of the breasts with reduction mammoplasty. Tissues with cysts, fibrosis, hamartomas, and fibroadenomas were dissected. Histopathology revealed extensive fibrosis with hamartomas and fibroadenomas. The immunohistochemical examination of the breast tissue showed a high level (70%) of estrogen and progesterone receptors expression. We prescribed hormone therapy with tamoxifen 10 mg per day. Dynamic monitoring of the treatment result and control of the disease remission was carried out. Breast-conserving surgery performed in such patients can help alleviate the psychological, social, and physical disorders caused by VGM.

**Keywords:** idiopathic gigantomastia, virginal recurrent gigantomastia, pseudoangiomaticous stromal hyperplasia (PASH), endogenous hormone stimulation, reduction mammoplasty.

Virginal gigantomastia (VGM) is a benign disease of the breast, without a clearly established etiology that is manifested by a significant increase in a size and mass of one or both breasts, constant gradual growth, starting with early pubertal period in girls, before the first pregnancy and the lactation period. There is no unequivocal and clear definition of VGM [1–7]. According to statistics, this is a very rare disease. Dancey et al. [2] proposed three types of gigantomastia: 1) idiopathic spontaneous breast growth; 2) gigantomastia due to endogenous hormone stimulation; and

3) drug-induced gigantomastia. There were described cases of the mammary gland hypertrophy during pregnancy; breast hypertrophy in the patients with Beckwith — Wiederman syndrome, and breast hypertrophy after treatment with prednisolone or steroid hormones [8–12]. The uncontrolled excessive hyperplasia of the breasts leads to a significant increase in their sizes. Morphologically, this growth of breast tissue is manifested with multiple cysts, fibroadenomas, hamartomas, and fibrous strands. There is predominance of the growth of connective tis-

---

Citation: Cheshuk V, Anikusko M, Kozina V. Virginal recurrent gigantomastia (breast hypertrophy). A case report. *Exp Oncol*. 2024; 46(1): 73-77. <https://doi.org/10.15407/exp-oncology.2024.01.073>

© Publisher PH «Akadempriodyka» of the NAS of Ukraine, 2024. This is an open access article under the CC BY-NC-ND license (<https://creativecommons.org/licenses/by-nc-nd/4.0/>)

sue over glandular tissue. The presence of areas of connective tissue in cases of gigantomastia is more known as an idiopathic pseudoangiomas-tous stromal hyperplasia (PASH) of the breast, which is a predominant pathological process in the breast tissue [1, 4, 6].

The main clinical symptoms are pain in the breast, dense nodes, and back pain due to the physical exertion caused by carrying a significant mass of breasts (2–10 kg) along with physical, aesthetic, and psychological discomfort. Breast mammography, MRT, and ultrasound examination confirm this pathological process (multiple cysts, fibroadenomas, hamartomas, and fibrous strands). Trepan biopsy of the most suspicious lesions is mandatory in order to rule out a malignant process and confirm this disease.

The treatment in most cases is surgical and also combined with hormone therapy. Most specialists recommend subcutaneous mastectomy with immediate implant reconstruction. An incomplete resection of the breast tissue, in the case of reduction mammoplasty, is possible when using combined treatment with anti-estrogens (tamoxifen) or agonists of luteinizing and follicle-stimulating hormones to prevent the growth. However, this does not guarantee that recurrences will not develop. Some authors recommend pregnancy to patients, during which a healthy transformation of the gland (differentiation of tissue for lactation) is possible. But there have been described cases of uncontrolled hyperplasia during gestation, which requires forced surgical intervention during pregnancy because of pathological stromal hyperplasia, while differentiation and physiologic hyperplasia of the glands does not develop [13–15].

**Case description.** The work was reported in line with the SCARE criteria. In 2014, a patient T. was operated for juvenile breast hypertrophy of both breasts. The reduction mammoplasty with incomplete removal of hypertrophied nodes was performed (Fig. 1). The patient wished to preserve breasts and reduce their size.

The patient began to notice the growth of the glands from the age of 12 simultaneously with the appearance of her first menses, and she paid attention on that before each periodicity, the glands swelled but then the swelling did not decrease, and thus the gradual growth of the breasts to size 6–7 took place with their asymmetry: the right gland

was significantly larger, and gigantomastia was distressing, disabling, and deforming.

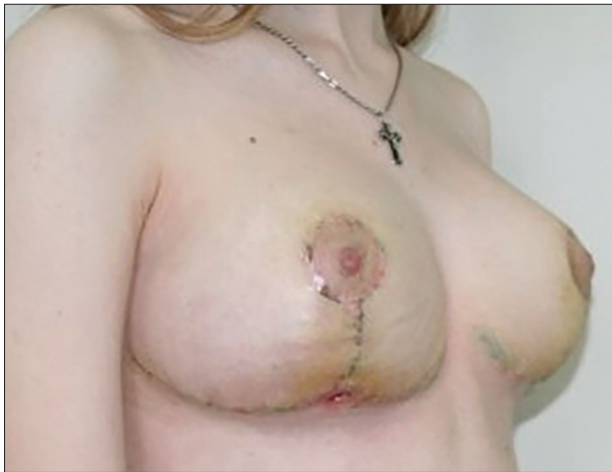After the operation, until 2019, there was a remission and the growth of the breasts did not develop. In 2019, the patient noticed the appearance of nodes in the left breast and the growth of both breasts, and in that case, more intensively on the left side (Fig. 2).

The patient did not know the exact reasons that could cause the growth of the breasts. A trepan biopsy of the nodes in the breasts was performed, and PASH was histologically established. The patient did not take any medication. In 2023, she emigrated because of the war to Poland, and in May 2023 she came to our clinic, where she was operated and underwent reduction mammoplasty. Before the operation, the patient underwent MRI of the breasts with contrast to determine the size of the pathological formations and exclude a possible malignant process. In conclusion, the MRI of the breasts described strong fibrous changes and multiple hamartomas, up to 20–60 mm in size, adenomas, fibroadenomas, and cysts (Fig. 3).

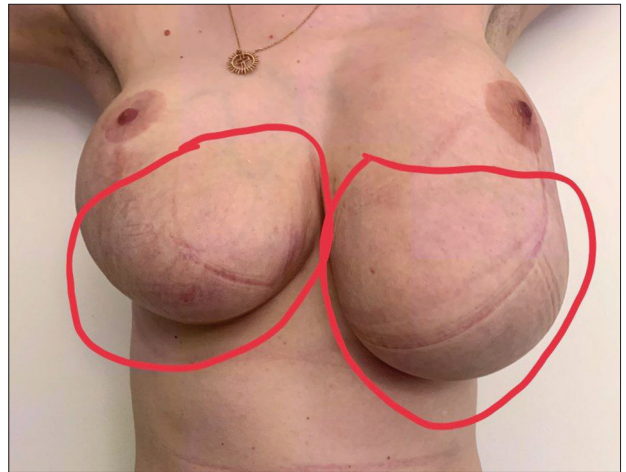
She had no pregnancies, no history of drug intake, alcohol and smoking. Her weight was 59 kg, height 162 cm, and BMI was 22.48 kg/m<sup>2</sup>. Biochemical and hematological analyses showed normal values.

The patient was asked about the method of the surgical intervention, it could be mastectomy or breast-conserving surgery with the reduction mammoplasty. The patient insisted on preserving breasts, although she did not object to a full mastectomy, but a bilateral breast reduction and mammoplasty were performed (June 7, 2023). The preoperative markings of the patient are shown in Fig. 4. During the operation, tissue with cysts, fibrosis, hamartomas, and fibroadenomas were detected and removed from the breasts (Fig. 5). The removed specimen weighted 2.3 kg on the left and 1.7 kg on the right breast.

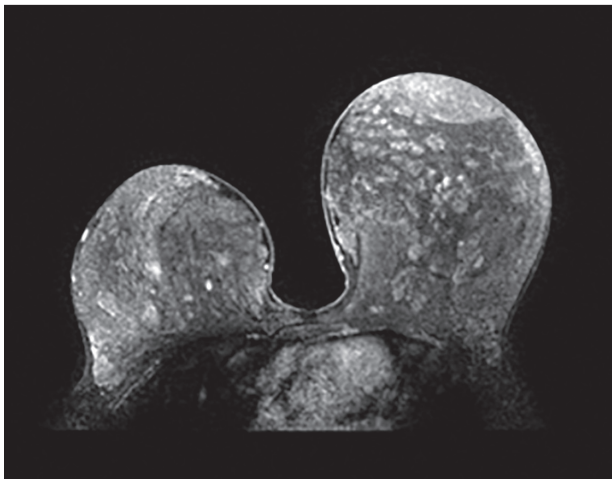
The largest formations were removed but we cannot deny the possibility of leaving small fibroadenomas because they were scattered throughout the breasts and it would be possible to dissect them completely when performing a subcutaneous mastectomy with a subsequent reconstruction. According to the pathohistological report, hamartomas and fibroadenomas without signs of malignancy were found in the removed mate-



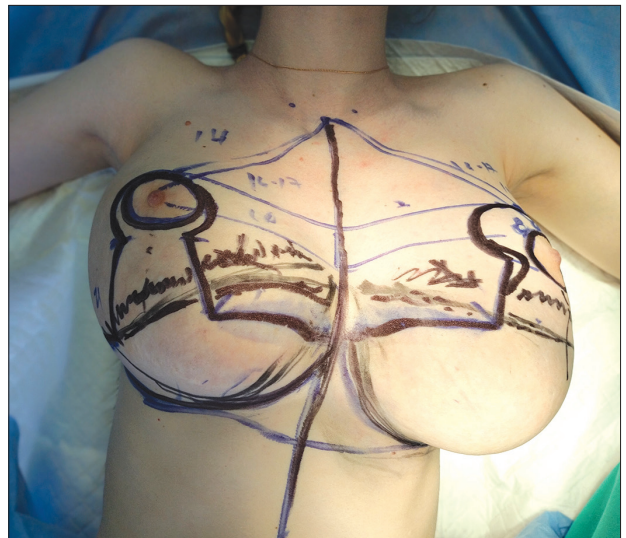
**Fig. 1.** The patient after surgery and reduction mammoplasty with incomplete removal of hyperplasia nodes in both breasts



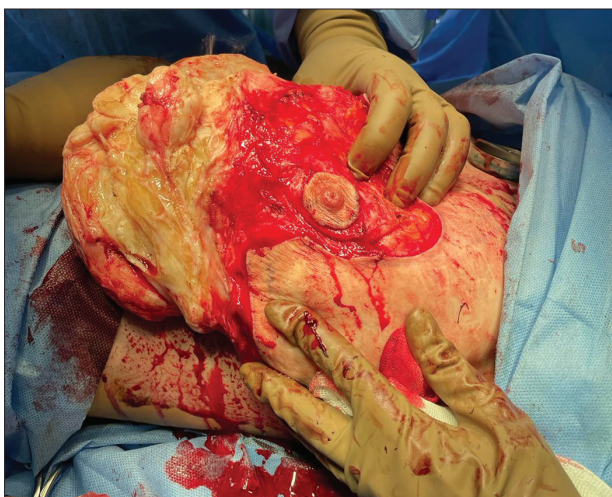**Fig. 2.** A 26-year-old patient before repeated surgery due to breast hyperplasia. The left breast is much larger than the right one



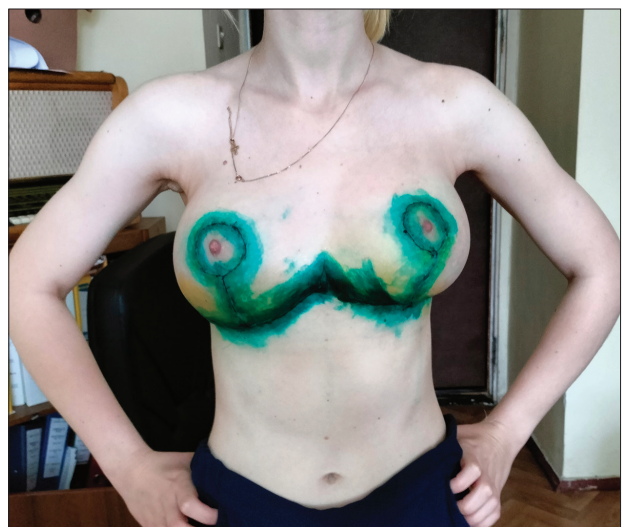**Fig. 3.** MRI of the breasts shows strong fibrous changes and multiple hamartomas, up to 20–60 mm in size, adenomas, fibroadenomas, and cysts



**Fig. 4.** Pre-operative markings of the patient



**Fig. 5.** Specimen with cysts, fibrosis, hamartomas, and fibroadenomas were detected and removed



**Fig. 6.** The patient after surgery

rial against the background of fibrocystic changes in the tissue of the breasts. The immunohistochemical evaluation of estrogen and progesterone receptors in the specimens showed their presence with a high level of expression (70%). The postoperative period was without complications (Fig. 6). Tamoxifen 10 mg per day was prescribed as the first line of hormone therapy to prevent recurrence of hyperplasia.

**Discussion.** VGM has some synonyms: juvenile idiopathic breast hypertrophy, juvenile macromastia, adolescent hypertrophy, which describe a rapid development of one or both breasts. It is a rare sporadic condition that occurs before menarche. Clear causes for the development of VGM have not been established, and most specialists think of a multifactorial etiology, but the endocrine theory is considered to be in the first place [13]. The main reason can be high sensitivity of estrogen receptors in the breast and abnormal ratio between estrogens and progesterone. The influence of sex hormones and all other reasons provoke the manifestation of this disease [14].

Laboratory tests for oestradiol, progesterone, luteinizing hormone, follicle-stimulating hormone, and prolactin were routinely indicated but they did not reveal any abnormalities in our case. Breast imaging is complicated due to the dense breast tissue, so MRI is optimal and excludes other breast pathologies.

The treatment of VGM is surgical management, medical therapy alone or after surgery. The surgical management options are subcutaneous mastectomy with implant reconstruction and reduction mammoplasty [14, 15]. A standard Wise-pattern breast reduction was performed in our case. An inverted-T scar is a result of the Wise-pattern incision used for dissection of inferior-central parts of both breasts.

Certainly, the surgical methods are too traumatic (subcutaneous mastectomy with endoprosthesis or too traumatic resection with a cosmetic defect). Nevertheless, since VGM is not a malignant disease, the data of histological examination allow preserving the breasts, which is a priority goal in adolescence.

The main method of the conservative treatment, along with the surgical treatment, is hormone therapy such as in hormone sensitive breast cancer (luminal type). We performed immunohistochemical evaluation of estrogen and progesterone receptors in the specimens demonstrating the presence of estrogen and progesterone receptors with a high level of expression (70%). Conservative treatment comprised mainly tamoxifen. According to the literature, the agonists of luteinizing and follicle-stimulating hormones also may be used [16] while the evidence of their efficacy is unknown. We prescribed tamoxifen 10 mg/day for 6 months with MRT evaluation.

Sometimes after breast-conserving surgery, pregnancy may be recommended to patients with a hope of healthy differentiation of breast tissue during the gestation period. But such a recommendation may be wrong given the described cases of pathological hyperplasia during pregnancy [17–19]. Therefore, breast-conserving surgery with adjuvant hormone therapy may be recommended. These data are under investigation.

Endogenous hormone stimulation is considered the most common etiological factor of recurrent VGM. Reduction mammoplasty with adjuvant hormone therapy is a variant of treatment of such young patients with risk of recurrence. The breast-conserving surgery performed in such patients can help alleviate the psychological, social, and physical disorders caused by this disease.

## REFERENCES

1. Vashistha A, Rundla M, Khan F, Om P. Idiopathic gigantomastia with pseudoangiomatous stromal hyperplasia: a case report. *Int J Surg. Case Rep.* 2020;77:915-919. <https://doi.org/10.1016/j.ijscr.2020.09.151>
2. Dancey A, Khan M, Dawson J, Peart F. Gigantomastia — a classification and review of the literature. *J Plast Reconstr Aesthet Surg.* 2008;61:493-502. <https://doi.org/10.1016/j.bjps.2007.10.041>
3. Wolfswinkel EM, Lemaine V, Weathers WM, et al. Hyperplastic breast anomalies in the female adolescent breast. *Semin Plast Surg.* 2013;27(1):49-55. <https://doi.org/10.1055/s-0033-1347167>
4. Sornlertlumvanich M, Rohitopakarn P, Samphao S, et al. Repeated recurrence of bilateral gigantomastia after subcutaneous mastectomy caused by tumoral pseudoangiomatous stromal hyperplasia: a case report and review of literature. *BJR Case Rep.* 2023;9(1):20220074. <https://doi.org/10.1259/bjrcr.20220074>
5. Hoppe IC, Patel PP, Singer-Granick CJ, Granick MS. Virginal mammary hypertrophy: a meta-analysis and treatment algorithm. *Plast Reconstr Surg.* 2011;127(6):2224-2231. <https://doi.org/10.1097/PRS.0b013e3182131bd1>

6. Jean-Louis WF, Bowder A, Dupont CR, et al. Extreme gigantomastia caused by pseudoangiomatous stromal hyperplasia at Hopital Universitaire de Mirebalais: a case report. *Plastic Reconst Surg Global Open*. 2021;9(12):e3960. <https://doi.org/10.1097/GOX.0000000000003960>
7. Pokhrel B, Gautam S, Sharma S, Pokhrel NB, Bhatta NC, Rayamajhi S, Shrestha JM. Virginal breast hypertrophy in a 14-year-old girl: A case report. *Clin Case Rep*. 2020;9(1):198-202. <https://doi.org/10.1002/ccr3.3498>
8. Jabaiti S, Fayyad L, Isleem U. Prednisolone-induced virginal mammary hypertrophy: Case report. *Int J Surg Case Rep*. 2019;59:140-143. <https://doi.org/10.1016/j.ijscr.2019.04.042>
9. Szymańska E, Moszczyńska E, Polnik D, et al. Virginal breast hypertrophy in a patient with Beckwith — Wiedemann syndrome. *Clin Case Rep*. 2018;6(3):484-489. <https://doi.org/10.1002/ccr3.1362>
10. Das L, Rai A, Vaiphei K, Garg A, et al. Idiopathic gigantomastia: newer mechanistic insights implicating the paracrine milieu. *Endocrine*. 2019;66(2):166-177. <https://doi.org/10.1007/s12020-019-02065-x>
11. Kasielska-Trojan A, Pietrusiński M, Bugaj-Tobiasz M, et al. Genetic factors of idiopathic gigantomastia: clinical implications of aromatase and progesterone receptor polymorphisms. *J Clin Med*. 2022;11(3):642. <https://doi.org/10.3390/jcm11030642>
12. Nguyen NJ, Sanchez LM, Yassa M, et al. Idiopathic gigantomastia in a patient on polypharmacy. *BJR Case Rep*. 2021;7(5):20210052. <https://doi.org/10.1259/bjrcr.20210052>
13. Mareti E, Vatopoulou A, Spyropoulou GA, et al. Breast disorders in adolescence: a review of the literature. *Breast Care (Basel)*. 2021;16(2):149-155. <https://doi.org/10.1159/000511924>
14. Patel K, Corcoran J. Breast reduction surgery in adolescents. *Pediatr Ann*. 2023;52(1):31-35. <https://doi.org/10.3928/19382359-20221114-06>
15. Hisham A, Abd Latib M, Basiron N. Juvenile breast hypertrophy: a successful breast reduction of 14.9% body weight without recurrence in a 5-year follow-up. *Case Rep Surg*. 2017;3491012. <https://doi.org/10.1155/2017/3491012>
16. Baker SB, Burkey BA, Thornton P, LaRossa D. Juvenile gigantomastia: presentation of four cases and review of the literature. *Ann Plast Surg*. 2001;46(5):517-525. <https://doi.org/10.1097/0000637-200105000-00011>
17. Benali S, Kouach J. Bilateral gestational gigantomastia. *Pan Afr Med J*. 2021;39:16. <https://doi.org/10.11604/pamj.2021.39.16.29374>
18. Zhou M, Jin M, Wang L, Pan LJ. Pregnancy-associated gigantomastia recurrence and ectopic breast after reduction mammoplasty: a case report. *Cancer Biomark*. 2017;20(2):225-229. <https://doi.org/10.3233/CBM-160450>
19. Saha S. Gestational gigantomastia with massively haemorrhagic ulcers. *Postgrad Med J*. 2022;98(1156):151-152. <https://doi.org/10.1136/postgradmedj-2020-139159>

Submitted: November 29, 2023

В. Чешук<sup>1</sup>, М. Анікусько<sup>2</sup>, В. Козіна<sup>2</sup>, В. Уліщенко<sup>1</sup>, М. Малець<sup>2</sup>

<sup>1</sup> Національний медичний університет імені О.О. Богомольця, Київ, Україна

<sup>2</sup> Київський міський клінічний онкологічний центр, Київ, Україна.

#### РЕЦИДИВ ВІРГІНАЛЬНОЇ ГІГАНТОМАСТІЇ (ГІПЕРТРОФІЇ ГРУДНОЇ ЗАЛОЗИ): КЛІНІЧНИЙ ВИПАДОК

Віргінальна гігантмастія (ВГМ) — доброякісне захворювання грудної залози без чітко встановленої етіології. Більшість фахівців рекомендують пацієнтам із ВГМ підшкірну мастектомію з реконструкцією імплантатом або редукційну мамопластику. Хвора з ВГМ була прооперована в 2014 р, а також виконано редукційну мамопластику. Через 9 років у пацієнтки стався рецидив і було проведено повторну операцію — резекцію грудних залоз з редукційною мамопластиком. Гістологічне дослідження продемонструвало наявність кіст, фіброзів, гамартом та фіброаденом. Імуногістохімічне дослідження тканин грудної залози виявило високий рівень (70%) експресії рецепторів до естрогену та прогестерону. Призначено гормонотерапію тамоксифеном по 10 мг на добу. Проводиться динамічне спостереження за результатом лікування та контроль ремісії захворювання. Головне питання — як лікувати ВГМ? Консервативне лікування є неефективним. Операція занадто травматична. Тому редукційна мамопластика з ад'ювантною гормонотерапією є варіантом лікування таких молодих пацієнтів із ризиком рецидиву. Операції зі збереження грудей, які виконуються у таких хворих, можуть полегшити психологічні, соціальні та фізичні розлади, спричинені ВГМ.

**Ключові слова:** ідіопатична гігантмастія, віргінальна рецидивна гігантмастія, псевдоангіоматозна стромальна гіперплазія (ПАСГ), ендогенна гормональна стимуляція, редукційна мамопластика.